



# Fractional CO<sub>2</sub> laser for genitourinary syndrome of menopause in breast cancer survivors: clinical, immunological, and microbiological aspects

Angelamaria Becorpi<sup>1</sup> · Giuseppina Campisciano<sup>2</sup> · Nunzia Zanotta<sup>2</sup> · Zelinda Tredici<sup>1</sup> · Secondo Guaschino<sup>1</sup> · Felice Petraglia<sup>1</sup> · Annalisa Pieralli<sup>1</sup> · Giovanni Sisti<sup>1</sup> · Francesco De Seta<sup>2,3</sup> · Manola Comar<sup>2,3</sup>

Received: 7 August 2017 / Accepted: 20 February 2018 / Published online: 1 March 2018  
© Springer-Verlag London Ltd., part of Springer Nature 2018

## Abstract

The composition of vaginal microbiome in menopause and cancer survivor women changes dramatically leading to genitourinary syndrome of menopause (GSM) in up to 70% of patients. Recent reports suggest that laser therapy may be valuable as a not hormonal therapeutic modality. The aim of the present study was to evaluate the effects of fractional CO<sub>2</sub> laser treatment on the vaginal secretory pathway of a large panel of immune mediators, usually implicated in tissue remodeling and inflammation, and on microbiome composition in postmenopausal breast cancer survivors. The Ion Torrent PGM platform and the Luminex BioPlex platform were used for microbiome and immune factor analysis. The significant reduction of clinical symptoms and the non-significant changes in vaginal microbiome support the efficacy and safety of laser treatment. Moreover, the high remodeling status in vaginal epithelium is demonstrated by the significant changes in inflammatory and modulatory cytokine patterns. Laser therapy can be used for the treatment of GSM symptoms and does not show any adverse effects. However, further studies will be needed to clarify its long-term efficacy and other effects.

**Keywords** Fractional CO<sub>2</sub> laser · Cytokines/chemokines · Microbiome · Menopause · Breast cancer

## Abbreviations

VVA	Vulvovaginal atrophy
GSM	Genitourinary syndrome of menopause
VRS	Verbal Rating Scale
BV	Bacterial vaginosis
VHI	Vaginal Health Index
FSFI	Female Sexual Function Index

FSDSr Female Sexual Distress Scale revised 2005

## Introduction

In menopause, the lack of estrogen is associated with diminished collagen, elastin, hyaluronic acid content, thinned

✉ Manola Comar  
manola.comar@burlo.trieste.it

Angelamaria Becorpi  
becorpia@aou-careggi.toscana.it

Giuseppina Campisciano  
giusi.campisciano@burlo.trieste.it

Nunzia Zanotta  
nunzia.zanotta@burlo.trieste.it

Zelinda Tredici  
ztredici@yahoo.it

Secondo Guaschino  
secondo.guaschino@unifi.it

Felice Petraglia  
felicepetraglia@unisi.it

Annalisa Pieralli  
pierallia@aou-careggi.toscana.it

Giovanni Sisti  
giovanni83@email.it

Francesco De Seta  
francesco.deseta@burlo.trieste.it

<sup>1</sup> Section of Gynecology and Obstetrics, Department of Woman and Child Health, Careggi University Hospital, Largo Brambilla 3, 50144 Florence, Italy

<sup>2</sup> Institute for Maternal and Child Health-IRCCS “Burlo Garofolo”, via dell’Istria 65/1, 34100 Trieste, Italy

<sup>3</sup> Department of Medical Sciences, University of Trieste, Piazzale Europa 1, 34127 Trieste, Italy

epithelium, impaired smooth muscle proliferation, denser connective tissue arrangement, loss of vascularity, and impaired prolubricative and proelastic functions. The anatomical and functional defects predispose to irritation and sexual trauma and may lead to changes in sexual and urinary organs [1]. The classical symptoms are dyspareunia and dysuria, sometimes accompanied by recurrent urinary tract infections and other symptoms, eventually characterizing the syndrome called vulvovaginal atrophy (VVA) or, according to the most recent classification, genitourinary syndrome of menopause (GSM) [2]. All of these symptoms significantly affect the quality of life of menopausal women [3]. In breast cancer survivors, atrophic vaginitis/vaginal dryness can affect up to 70% of the postmenopausal patients when compared to postmenopausal women without breast cancer [4, 5]. The use of hormonal therapies improves menopausal syndrome, sexual health, and quality of life [1], although in postmenopausal women with a history of estrogen-dependent neoplasia, vaginal estrogen therapy is controversial and the most recent guidelines recommend co-management with the woman's oncologist [6]. In addition, breast cancer survivors, after surgery, usually receive further chemo-, hormonal, and radiotherapy that can aggravate the vaginal symptoms. In these patients, moisturizing treatments or lubricants are safe and indicated, even if they carry low compliance and they are less effective than hormonal therapies [7]. In the last few years, it has been suggested that laser therapy may be valuable as a non-hormonal therapeutic modality in the management of GSM [8]. There are approximately 15 laser companies in the market, the majority providing products based on the CO<sub>2</sub> and erbium:yttrium-aluminum-garnet (Er:YAG) lasers, and the interest in the use of these lasers as a non-hormonal option for the treatment of GSM has [9, 10].

Zerbinati et al. [11] have shown that the use of the micro-ablative carbon dioxide laser on the vaginal epithelial resurfacing activates heat shock proteins that in turn activate growth factors, stimulating the increase of acidic mucopolysaccharides in the ground matrix and the increase of glycogen content in the vaginal epithelial cells, with an increasing thickness of vaginal epithelium. Further studies have shown that the restoring of correct composition of the extracellular matrix produces a correct permeability of the connective favoring the passage of the different nutrients from the capillaries to the tissues. Particularly, the circulating estrogens produced in this phase in the adrenal gland and adipose tissue reach vaginal epithelial cells, which, since do not lose estrogen receptors in menopause, are stimulated to proliferate also with low estrogenic levels [12, 13].

Salvatore et al. [14] recently have published a pilot study on the treatment of VVA in postmenopausal women using fractional CO<sub>2</sub> laser where they observed morphological changes of collagen fibers in the vaginal epithelial tissue after treatment; these effects were associated with improvement of

VVA symptoms and patient quality of life. In particular, preliminary results of laser therapy efficacy have been reported on specific symptoms of VVA, such as sexual function [14] and vulvovaginal atrophy [15], vaginal flora [16], and GSM as a whole [17], and improvements were observed on women with idiopathic vestibulodynia or caused by GSM [18].

Accordingly with previous studies, our research team has shown the efficacy of the thermo-ablative fractional CO<sub>2</sub> laser in relieving dyspareunia symptoms in breast cancer survivor patients [19].

In the last few years, a growing body of evidence has suggested that vaginal health depends on a balance of several factors where the host local immunity and microbiome play a key role. Particularly, the composition of vaginal microbiome changes in menopause [20–22] and it is additionally modified by cancer survivor status could be some of the factors that cause GSM. A number of animal and human studies have shown that the levels of cytokines in cervicovaginal lavage (CVL) positively correlate with histopathology and clinical signs of vaginal inflammation, and that estrogens influence the activity of cytokines in the reproductive tract [23–26]. In the light of all these evidences, the aim of the present study was to evaluate the effects of laser treatment on vaginal immune mediators and microbiome of breast cancer women. Specifically, a secretory pathway of a large panel of immune mediators, usually implicated in tissue remodeling and inflammation, and microbiome composition were analyzed in postmenopausal cancer survivor women after vaginal mucosa treatment with fractional CO<sub>2</sub> laser.

## Materials and methods

### Patients

This is a clinical prospective study in consecutive postmenopausal patients who were referred to our clinic from December 2015 to February 2016 for one or more symptoms and signs related to GSM.

All women were postmenopausal and breast cancer survivors, and laser treatment was chosen as preferred therapy for vaginal symptoms as opposed to hormonal therapy, given the sensitivity of this population to estrogen levels. All patients underwent vaginal treatment with fractional CO<sub>2</sub> laser.

The inclusion criteria consisted of menopausal status, diagnosis of vaginal atrophy, patients with previous breast cancer, and PAP tests negative performed within 1 year of selection visit.

The diagnosis of vaginal atrophy was placed if there were the following signs and symptoms:

- “Vaginal dryness” as a symptom reported by the woman

- At least a sign of the following documented by the physician: flattening of the vaginal folds, dryness of the vaginal mucosa, pallor of the vaginal mucosa, fragility of the mucosa, and petechiae
- Vaginal pH > 5

Patients with active genital infections (bacterial vaginosis, *candida* vaginitis, and aerobic vaginitis), patients with clinically significant systemic diseases that may interfere with the study, patients with previous cancer of the vagina, cervix, or endometrium, patients previously treated with radiotherapy local, and/or the use of therapies vaginal moisturizers or lubricants in place were excluded from the study.

All the patients had completed the cancer treatment protocol and final evaluation within the study time.

All patients had discontinued therapy local vaginal moisturizing and/or lubricating at least 30 days, and the reasons for discontinuation of treatment were as follows: “Cream and/or vaginal suppositories tend to get out of the vagina” for seven patients; “therapies do not seem effective” for six patients; one had discontinued treatment for “local irritation”; one patient said that the vaginal applicator “is not easy to use,” and five patients were offered laser treatment as first choice.

The study was approved by the Ethics Committee of Florence. All patients who were recruited for the study signed an informed consent form. The study was conducted in accordance with the Declaration of Helsinki. This study was supported by the Italian Ministry of Health, grant number RC 26/13.

## Laser treatment

Each patient was treated with the fractional CO<sub>2</sub> laser system (SmartXide2 V2LR, Monalisa Touch®, DEKA, Florence, Italy) using the vaginal probe at the Service of Laser Surgery and Colposcopy Daimi, AOU Careggi, Florence. All laser application are performed in an outpatient setting, and they did not require local anesthesia or other preparation. During the first and second treatment, the laser energy is set at 30-W power and transmitted through an intravaginal probe with a dwell time of 1000 μs, a dot spacing of 1000 μm, and a smart stack parameter of 1, following a protocol of application used in previous authors’ studies [27]. Laser energy is released by two single shots oriented at 45° one from the other so to treat the entire circular vaginal surface covered by the probe which is dotted of two opposite focusing points, without touching the uterine cervix [19]. These parameters were selected on the basis on ex vivo studies conducted on vaginal wall specimen, which demonstrated connective tissue remodeling [28]. The total exposure time for patient was approximately 3–5 min.

## Clinical evaluation

The clinical evaluation of efficacy was performed individually for each of the following parameters which were carried during the screening visit (T0) and after 30 days from the second laser treatment (T1):

- Positioning of the speculum and observation of the vagina; signs of VVA were evaluated (flattening of the vaginal folds, dryness of the vaginal mucosa, pallor of the vaginal mucosa, fragility of the mucosa, petechiae) using a Verbal Rating Scale (VRS). Each parameter was graded from 0 (no symptom) to 3 (serious symptom)
- Vaginal swab for culture of bacteria and *Candida* spp. and Gram staining (Nugent score) for diagnosis of bacterial vaginosis (BV)
- Vaginal Health Index (VHI), which consisted of the following five parameters: elasticity, fluid volume, pH, epithelial integrity, and moisture. Each parameter was graded from 1 (worst condition) to 5 (best condition)
- Vaginal swab for the study of vaginal immunity and microbiome: the swab was scraped on the vaginal wall side (left and right) and then stored in a test tube with inside physiologic solution at – 20 °C
- Intensity of VVA symptoms was evaluated (vaginal itching, vaginal burning, vaginal dryness, dyspareunia, and dysuria) using a VRS. Each parameter was graded from 0 (no symptom) to 3 (serious symptom)
- Survey on the sexual function (the Female Sexual Function Index—FSFI) and survey on the sexual distress (the Female Sexual Distress Scale revised 2005—FSDSr).

At T1, treatment satisfaction was evaluated using a 5-point Likert scale (very satisfied, satisfied, uncertain, dissatisfied, and very dissatisfied).

Eventual adverse events which occurred or were referred by patients (during, immediately after treatment sessions, and until the end of study) were recorded.

## Statistical analysis

Statistical analysis was performed using SPSS version 22.0 (Chicago, IL). The comparison between the variables mentioned above, before and after treatment with the laser fractionated CO<sub>2</sub>, was performed by non-parametric paired Wilcoxon test or not paired Mann-Whitney test, as indicated. As a test of normality, the Shapiro-Wilk test was used. Shannon diversity (*H*) and equitability index were calculated and compared between the microbiomes before and after laser treatment. Statistical significance was set at  $p < 0.05$ . All the variables were not normally distributed.

## Microbiome analysis

DNA extraction from the aliquots of 500  $\mu$ l was carried out using the NucliSENS® easyMAG® system (BioMérieux, Gorman, NC, USA). All DNA samples were stored at  $-20$  °C prior to Ion Torrent sequencing. A real-time quantitative EvaGreen® dye (Fisher Molecular Biology, Waltham, USA) PCR was performed with the degenerated primer 27FYM (5'-AGR GTT YGA TYM TGG CTC AG-3') and with the U534R primer (primers target the V1–V3 region, spanning 500 bp). A nested PCR was performed with the primers B338F\_P1-adaptor (B338F 5'-ACTCCTACGGGAGGCAGC-3') and U534R\_A\_barcode (U534R 5'-ATTACCGCGGCTGCTGG-3') to prepare a 200 base template for the final V3 region sequencing, in association with the Ion Xpress Barcode Adapter. The PCR reactions were performed using the Kapa 2G HiFi Hotstart ready mix 2 $\times$  (Kapa Biosystems, MA, USA) and BSA 400 ng/ $\mu$ l, under the following conditions: 5 min at 95 °C, 30 s at 95 °C, 30 s at 59°/57 °C, 45 s at 72 °C, and a final elongation step at 72 °C for 10 min. The size of the amplicon (260 bp) was checked on a 5% acrylamide gel. The amount of DNA was quantified with a Qubit® 2.0 Fluorometer (Invitrogen, Carlsbad, CA, USA). The pooled library was diluted to a concentration of 26 pM. Template preparation was performed using the Ion PGM Template OT2 200 kit on Ion OneTouch™ 2 System (Thermo Fisher Scientific, Waltham, MA, USA) and the subsequent quality control was carried out on Qubit® 2.0 Fluorometer. The templates were sequenced on the Ion PGM™ System machine, using the Ion PGM sequencing 200 KIT V2 (Thermo Fisher Scientific, Waltham, MA, USA). QIIME 1.8.01 was used to process the sequence data [21].

## Vaginal cytokine analysis

The analysis of a 48 cytokine and chemokine panel (including IL-1 $\beta$ , IL-1ra, IL-2, IL-4, IL-5, IL-6, IL-7, IL-8, IL-9, IL-10, IL-12(p70), IL-13, IL-15, IL-17, eotaxin, basic FGF, G-CSF, GM-CSF, IFN- $\gamma$ , IP-10, MCP-1, MIP-1 $\alpha$ , PDGF-BB, MIP-1 $\beta$ , RANTES, TNF- $\beta$ , VEGF, IL-1 $\alpha$ , IL-2R $\alpha$ , IL-3, IL-12(p40), IL-16, IL-18, CTACK, GRO- $\alpha$ , HGF, IFN- $\alpha$ 2, LIF, MCP-3, M-CSF, MIF, MIG,  $\beta$ -NGF, SCF, SCGF- $\beta$ , SDF-1 $\alpha$ , TNF- $\alpha$ , and TRAIL) was assessed in duplicate performed on vaginal swab using a magnetic bead-based multiplex immunoassays (Bio-Plex®) (BIO-RAD Laboratories, Milano, Italy) following manufacturers' instructions. In brief, 50  $\mu$ l of indiluted vaginal swab and standards was added in duplicate to a 96 multi-well plate containing analyte magnetic beads. After incubation for 30 min at room temperature, wells were then washed three times with Bio-Plex wash buffer, and 25  $\mu$ l of the premixed detection antibodies was added to the wells. This was followed by incubation for 30 min. After washing, 50  $\mu$ l of streptavidin-PE was added to the wells and the plate was incubated for 10 min with shaking. The

concentrations of the cytokines were determined using the Bio-Plex array reader (Luminex, Austin, TX). The data were analyzed using Bio-Plex Manager software (v.5, Bio-Rad) and were expressed as median fluorescence intensity (MFI) and concentration (pg/ml) [22].

**Data availability** The dataset was deposited in the Short Read Archive (PRJNA388787).

## Results

A total of 20 patients with breast cancer were enrolled in the study. All of the patients had surgical therapy: 16 have subsequent hormonal therapy, 3 subsequent radiotherapy, and 1 chemo-radiotherapy.

The average age was 58.2 years, the average body mass index was 23.7 kg/m<sup>2</sup>, and the average age of menarche was 12.4 years. Duration of menopausal status was 8.85  $\pm$  5.4 years.

Relevant demographic characteristics, pre-treatment clinical data, and inclusion/exclusion criteria were recorded at screening visit (T0). For each VRS parameter considered in the analysis for the VVA symptoms, a statistically significant improvement was recorded after the treatment except for dysuria (Table 1).

For Vaginal Health Index (VHI) and for the Female Sexual Function Index (FSFI), a statistically significant improvement was recorded after the laser treatment, while for the Female Sexual Distress Scale revised (FSDSr), no statistically significant improvement was recorded (Table 1).

We found higher levels of IL-18, CTACK, LIF, M-CSF, and IL-17 after treatment, while levels of IL-1ra, IL-2, IL-7, IL-9, IL-13, eotaxin, GM-CSF, and RANTES were lower after treatment (Table 2).

Levels of IL-1a, IL-2Ra, IL-3, IL-12p40, IL-16, GROa, HGF, IFN-a2, MCP-3, MIG, b-NGF, SCF, SCGF-b, SDF-1a, TNF-b, TRAIL, IL-1b, IL-4, IL-5, IL-6, IL-8, IL-10, IL-12(p70), FGF-basic, G-CSF, IFN-g, IP-10, MCP-1(MCAF), MIP-1a, PDGF-bb, MIP-1b, and TNF-1 did not statistically change after laser treatment (Table 2).

Regarding the relative proportion of bacteria in the vaginal environment, the Shannon diversity index *H* and equitability comparison before and after treatment did not yield any statistical significant results (Table 3). The relative proportion of bacteria did not differ before and after treatment (Fig. 1).

## Discussion

Micro-ablative fractional CO<sub>2</sub> method has been used as an effective tool for skin resurfacing and restoration [9], showing its remodeling connective tissue properties in many body

**Table 1** Symptoms, signs, VHI, FSFI, and FSDSr before and after CO<sub>2</sub> laser treatment. \*The variables are expressed as median (25th–75th percentile range)

Symptoms	Before the fractional CO <sub>2</sub> laser*	After the fractional CO <sub>2</sub> laser*	<i>p</i> (non-parametric paired Wilcoxon test)
Vaginal dryness	2 [2–3]	2 [1–2]	0.002
Dyspareunia	2 [2–3]	2 [1–2]	0.006
Vaginal itching	1 [0–2.75]	0 [0–1]	0.012
Vaginal burning	1 [0–3]	1 [0–1]	0.012
Dysuria	0 [0–1.75]	0 [0–0.75]	0.132
Flattening vaginal folds	2 [1.25–2.75]	1 [1–1]	0.000
Vaginal mucosa dryness	2 [2–2.75]	1 [0–1.75]	0.000
Vaginal pallor	2 [2–3]	1 [1–1]	0.000
Fragility of the mucosa	2 [1–2]	1 [0–1]	0.000
Petechiae	1 [0–1.75]	0 [0–1]	0.005
VHI	12 [11–13]	16 [15.25–18.00]	0.000
FSFI	27.5 [4–54.50]	43 [20.25–70.50]	0.003
FSDSr	21 [10–28]	15 [8.00–24.00]	0.074

**Table 2** Expression of immune mediators in vaginal swab pre- and post-treatment (pg/ml)

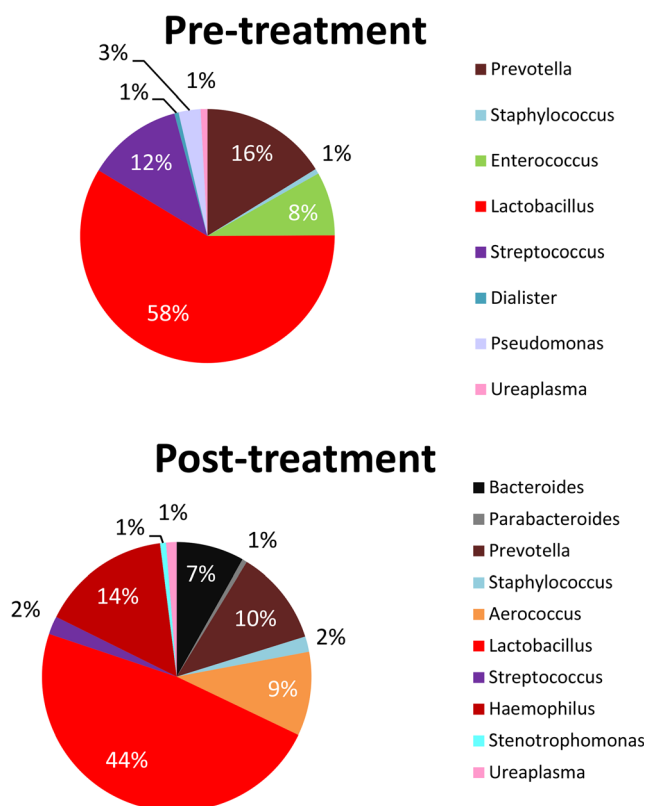
Vaginal fluid cytokines	Pre-treatment	Post-treatment	<i>p</i> value
Significantly upregulated cytokines after treatment			
IL-18	582.6 [251.01–1574.0725]	1729.35 [609.425–7017.5435]	0.15
CTACK	8.4150 [6.4125–11.5325]	11.2850 [6.412–18.31]	0.044
LIF	21.77 [14.8175–29.355]	30.4050 [17.1125–44.5825]	0.025
M-CSF	21.4 [14.9875–38.19]	42.93 [15.5050–66.8975]	0.028
IL-17	2.255 [1.29–7.6625]	9.47 [3.17–13.22]	0.028
Significantly downregulated cytokines after treatment			
IL-1ra	11,163.31 [8608.1525–16,511.5675]	9111.96 [5137.73–11,322.9675]	0.04
IL-2	1.1250 [0.91–1.3975]	0.94 [0.63–0.94]	0.018
IL-7	1.39 [0.77–2.0250]	0.48 [0.4050–0.7350]	0.000
IL-9	6.445 [3.915–8.5475]	2.92 [2.1825–6.88]	0.014
IL-13	1.245 [0.9775–1.73]	0.72 [0.6275–1.0275]	0.006
Eotaxin	16.3850 [10.85–40.9075]	12.34 [8.21–20.4625]	0.010
GM-CSF	67.4450 [60.99–74.765]	62.2350 [51.8678–65.9625]	0.01
RANTES	155.68 [62.5075–662.9350]	81.9450 [9.6275–163.1850]	0.004
Cytokines with no significant change after treatment			
IL-1a	10.3850 [1.4325–32.8250]	11.08 [1.62–82.8725]	0.1
IL-2Ra	68.9550 [45.9100–87.7225]	72.85 [48.0975–110.89]	0.279
IL-3	140.5650 [121.7900–184.3450]	169.39 [104.1525–282.6275]	0.117
IL-12p40	174.65 [107.9375–409.3875]	169.43 [23.3575–371.3050]	0.627
IL-16	86.23 [51.0775–134.6225]	69.425 [42.3675–148.8450]	0.970
GROa	507.5350 [259.9125–1209.9350]	582.6150 [194.2825–1180.66]	0.794
HGF	84.47 [25.5125–242.7950]	84.855 [36.34–143.455]	0.411
IFN-a2	46.08 [40.68–57.2850]	49.17 [40.6625–69.1850]	0.093
MCP-3	43.9050 [30.1450–81.94]	59.3650 [21.58–161.4975]	0.212
MIG	258.42 [249.055–696.2675]	399 [272.21–1448.2225]	0.332
b-NGF	1.96 [1.21–2.95]	3.5 [1.66–7.2975]	0.22
SCF	23.81 [12.61–41.8]	49.1950 [20.7625–68.6250]	0.28
SCGF-b	222.12 [151.4575–298.54]	409.58 [155.915–538.0675]	0.40
SDF-1a	133.05 [90.8975–182.84]	174.5850 [92.3075–256.8375]	0.212
TNF-b	1.63 [0.795–2.3575]	2.22 [0.87–3.89]	0.296
TRAIL	35.1750 [14.2825–72.0525]	32.96 [18.03–61.505]	0.823
IL-1b	1.5350 [0.68–10.2325]	4.64 [0.915–16.505]	0.370
IL-4	0.2150 [0.17–0.27]	0.155 [1.225–0.3725]	0.763
IL-5	0.46 [0.2025–0.6375]	0.2 [0.1550–0.39]	0.000
IL-6	1.125 [0.7950–1.76]	0.49 [0.45–1.2]	0.351
IL-8	244.39 [63.7–909.185]	195.1150 [41.5525–543.715]	0.550
IL-10	2.125 [1.71–3.6675]	1.74 [1.2675–3.4425]	0.370
IL-12(p70)	1.9450 [1.38–4.77]	1.775 [0.9725–6.7325]	0.247
FGF-basic	11.305 [8.35–13.0025]	13.5 [7.675–16.8650]	0.575
G-CSF	13.94 [9.9375–22.6375]	7.7950 [4.2925–16.2450]	0.263
IFN-g	5.19 [4.27–9.65]	3.93 [3.2050–6.4975]	0.198
IP-10	855.92 [320.9575–2162.1525]	840.7 [288.3050–2288.1175]	0.494
MCP-1(MCAF)	2.46 [2.1225–3.3275]	2.22 [1.8–3.12]	0.334
MIP-1a	0.94 [0.84–1.2025]	0.96 [0.845–1.1475]	0.654
PDGF-bb	16.77 [11.6875–24.7650]	10.075 [7.4875–13.7075]	0.33
MIP-1b	27.8850 [6.4650–44.1450]	22.65 [3.7175–107.58]	0.575
TNF-a	3.5 [2.9250–5.2075]	2.79 [2.3950–3.8675]	0.277

**Table 3** Comparison of bacterial diversity between cohorts. Bacterial diversity values are given as mean  $\pm$  standard deviation. Alpha diversity was compared between groups by means of a non-parametric *t* test using the compare\_alpha\_diversity.py script of QIIME. *p* values are shown in the last column

Index	Before treatment	After treatment	<i>p</i> value
Shannon	1.6 0.9	1.8 $\pm$ 1	0.702
Equitability	0.31 $\pm$ 0.15	0.34 $\pm$ 0.17	0.787

regions, and the ability to stimulate the production of collagen and elastic fibers. Indications of GSM symptom alleviation and improvement of sexual function satisfaction following the CO<sub>2</sub> laser therapy have been reported, bringing benefits especially in patients who cannot use estrogen therapy. Moreover, when laser treatment was compared with intravaginal estriol, the benefits of the CO<sub>2</sub> laser therapy were more pronounced and longer lasting compared with estriol [12, 13].

Previous data have suggested that specific laser irradiation parameters induced specific cellular activities, as cellular proliferation and a cell signaling cascade for the production and release of growth factors and cytokines, inducing the anti-inflammatory effect on the local tissue [23, 24]. Considering



**Fig. 1** The vaginal bacterial communities from patients before and after treatment. The output of plot\_taxa\_summary.py of QIIME showing the relative abundance of the predominant bacterial taxonomic groups in the studied cohorts

these findings, the aim of this study was to analyze the changes of vaginal cytokine profile and vaginal microbiome after CO<sub>2</sub> laser treatment and their possible role in improving symptoms of patients with VVA. A significant decrease in levels of pro-inflammatory cytokines, in particular IL-2 and IL-7, was observed after laser treatment, showing the action of this therapy on the inhibition of the release of certain inflammatory immune proteins. Another demonstration of the beneficial effect of this treatment is given by decrease of important inflammatory factors of cell-mediated immunity, such as RANTES, GM-CSF, and eotaxin, which attract monocytes, lymphocytes, basophils, and eosinophils in the inflammatory response. Conversely, the concentrations of some cytokines and growth factors, as IL-18, CTACK, LIF, and M-CSF, molecules usually involved in inflammatory processes, were found higher after laser therapy. Recent studies have shown that the laser irradiation on the skin increases cellular proliferation, viability of tissue, and remodeling of collagen. This mechanism induces an increase of inflammatory cytokine expression, pleiotropic proteins, which, in low concentrations, stimulate cell proliferation and migration, and they play an important role in tissue repair [29, 30]. Consistent with previous studies, the increase of concentration of IL-18, CTACK, LIF, and M-CSF proteins, in vaginal swab, could be the consequence of the remodeling status of the vaginal tissue after laser treatment. In particular, M-CSF is a growth factor involved in the pro-inflammatory immunologic mechanisms and it influences hematopoietic stem cells to differentiate into macrophages or other related cell types. M-CSF is particularly implicated in the steady-state control of tissue macrophage development and it has been proposed also to have a possible involvement in the resolution of inflammatory reactions. Following specific stimulations, this factor induces the differentiation of M2 macrophages which act as anti-inflammatory agents and resolve the inflammatory response not allowing more recruitment of other inflammatory cells and proceed in the tissue regeneration phase [31]. Prignano et al. [30] have conducted a study to verify the effects of fractional CO<sub>2</sub> laser on cytokine pathway of tissue repair of atrophic skin. The discrepancy observed in our study, where we did not find any statistically significant difference in b-FGF and PDGF expression after laser treatment, may be basically caused by two factors: (1) the different tissues involved (skin vs vaginal mucosa) and (2) the technique used for immune mediator analysis (immunohistochemical vs Bio-Plex platform) and laser parameters (different laser fluences).

It is well known that estrogen therapy is effective for the treatment of VVA, and, concomitantly, hormonal replacement increases the abundance of vaginal *Lactobacillus* spp. However, the independent contribution of the increase of *Lactobacilli* in improving VVA symptoms is not known. Data from Brotman provide evidence that there are differences in the bacterial communities between pre-, peri-, and

postmenopause, hypothesizing that the anaerobes may play a role in signs and symptomatology of VVA [32]. Instead, data from Shen [33] differ from those of Brotman et al. in so far as *Gardnerella* and *Atopobium* were the most frequent and abundant taxa in vaginal communities of women with AV and there was a statistically positive correlation between their prevalence and genital symptom scores. These compelling findings imply that strains of various bacterial species might be associated with the emergence of AV and that new therapeutic targets might emerge as more is learned about the possible causes of AV. In our data, the three bacterial genera *Lactobacillus*, *Prevotella*, and *Aerococcus* were within the five most represented in vaginal swab of pre- and post-treatment. *Streptococcus* and *Enterococcus* were more abundant before treatment while after treatment, *Haemophilus* and *Bacteroides* increased (Fig. 1). However, these differences of vaginal bacteria composition did not reach statistical significance.

Our study suggests that the beneficial effect of CO<sub>2</sub> laser treatment is primarily due to the biochemical and morphological changes of the epithelial vaginal cells which is associated with the expression of specific cytokines involved, basically, in anti-inflammatory process. Conversely, no change in composition of vaginal microbiome was documented. This may be related to the maintenance of a positive local balance able to favor the colonization of commensal microorganisms [16].

At our knowledge, this is the first study evaluating the effects of fractional CO<sub>2</sub> laser treatment in GSM by comparing the vaginal immunity with the vaginal microbiome in breast cancer women.

## Clinical practice

In breast cancer survivors, atrophic vaginitis/vaginal dryness can affect up to 70% of the postmenopausal patients when compared to postmenopausal women without breast cancer, leading to the genitourinary syndrome of menopause (GSM).

After surgery, breast cancer survivors receive further chemo-, hormonal, and radiotherapy, which can aggravate the vaginal symptoms.

Recent reports suggest that laser therapy may be valuable as a non-hormonal therapeutic modality in the management of GSM.

Preliminary results of laser therapy efficacy have been reported on specific symptoms of GSM, such as sexual function and vulvovaginal atrophy, vaginal flora, and GSM as a whole.

We also observed a significant reduction of clinical symptoms related to GSM after the CO<sub>2</sub> laser treatment, supporting its efficacy as therapy in postmenopausal cancer survivors. The high remodeling status in vaginal epithelium is demonstrated by the significant changes in inflammatory and modulatory cytokine patterns. The absence of modifications in the

vaginal microbiome after the treatment confirms the safety of the CO<sub>2</sub> laser. The availability of randomized controlled trials and well-designed case-control studies are required to further investigate the potential benefits, harm, and efficacy of laser therapy in the treatment of GSM symptoms.

## Conclusion

The significant reduction of clinical symptoms related to GSM after the CO<sub>2</sub> laser treatment supports its efficacy as therapy in postmenopausal cancer survivors. The high remodeling status in vaginal epithelium is demonstrated by the significant changes in inflammatory and modulatory cytokine patterns. The absence of modifications in the vaginal microbiome after the treatment confirms the safety of the CO<sub>2</sub> laser. The exact mechanism responsible for the clinical improvement is still to be elucidated and further studies are needed in this field to clarify its long-term efficacy and other effects. The availability of randomized controlled trials and well-designed case-control studies are required to further investigate the potential benefits, harm, and efficacy of laser therapy in the treatment of GSM symptoms.

**Authorship** Conceptualization, M.C.; methodology, A.M.B., G.C., and N.Z.; software, G.C. and N.Z.; investigation, A.M.B., G.C., and N.Z.; resources, Z.T., S.G., F.P., A.P., and G.S.; data curation, G.C. and N.Z.; writing—original draft, G.C., N.Z., and M.C.; writing—review and editing, M.C.; visualization, G.C. and N.Z.; funding acquisition, M.C.

**Funding** This study was supported by the Italian Ministry of Health, grant number RC 26/13.

## Compliance with ethical standards

**Conflict of interest** The authors declare that they have no competing interests.

**Ethics approval and consent to participate** The study was approved by the Ethics Committee of Florence. The study was conducted in accordance with the Declaration of Helsinki.

**Consent for publication** All patients who were recruited for the study signed an informed consent form.

## References

1. Gandhi J, Chen A, Dagur G, Suh Y, Smith N, Cali B, Khan SA (2016) Genitourinary syndrome of menopause: an overview of clinical manifestations, pathophysiology, etiology, evaluation, and management. *Am J Obstet Gynecol* 215(6):704–711. <https://doi.org/10.1016/j.ajog.2016.07.045>
2. Portman DJ, Gass ML (2014) Genitourinary syndrome of menopause: new terminology for vulvovaginal atrophy from the International Society for the Study of Women's Sexual Health and

- the North American Menopause Society. *Maturitas* 79(3):349–354. <https://doi.org/10.1016/j.maturitas.2014.07.013>
3. Nappi RE, Kokot-Kierepa M (2010) Women's voices in the menopause: results from an international survey on vaginal atrophy. *Maturitas* 67(3):233–238. <https://doi.org/10.1016/j.maturitas.2010.08.001>
  4. Lester J, Pahouja G, Andersen B, Lustberg M (2015) Atrophic vaginitis in breast cancer survivors: a difficult survivorship issue. *Journal of personalized medicine* 5(2):50–66. <https://doi.org/10.3390/jpm5020050>
  5. Crandall C, Petersen L, Ganz PA, Greendale GA (2004) Association of breast cancer and its therapy with menopause-related symptoms. *Menopause* 11(5):519–530
  6. Management of symptomatic vulvovaginal atrophy: 2013 position statement of The North American Menopause Society (2013). *Menopause* 20 (9):888–902; quiz 903–884. <https://doi.org/10.1097/GME.0b013e3182a122c2>
  7. Sturdee DW, Panay N (2010) Recommendations for the management of postmenopausal vaginal atrophy. *Climacteric : the journal of the International Menopause Society* 13(6):509–522. <https://doi.org/10.3109/13697137.2010.522875>
  8. Arunkalaivanan A, Kaur H, Onuma O (2017) Laser therapy as a treatment modality for genitourinary syndrome of menopause: a critical appraisal of evidence. *Int Urogynecol J* 28(5):681–685. <https://doi.org/10.1007/s00192-017-3282-y>
  9. Jih MH, Kimyai-Asadi A (2008) Fractional photothermolysis: a review and update. *Seminars in cutaneous medicine and surgery* 27(1):63–71. <https://doi.org/10.1016/j.sder.2008.01.002>
  10. Perino A, Calligaro A, Forlani F, Tiberio C, Cucinella G, Svelato A, Saitta S, Calagna G (2015) Vulvo-vaginal atrophy: a new treatment modality using thermo-ablative fractional CO2 laser. *Maturitas* 80(3):296–301. <https://doi.org/10.1016/j.maturitas.2014.12.006>
  11. Zerbini N, Serati M, Origoni M, Candiani M, Iannitti T, Salvatore S, Marotta F, Calligaro A (2015) Microscopic and ultrastructural modifications of postmenopausal atrophic vaginal mucosa after fractional carbon dioxide laser treatment. *Lasers Med Sci* 30(1):429–436. <https://doi.org/10.1007/s10103-014-1677-2>
  12. Stefano S, Stavros A, Massimo C (2015) The use of pulsed CO lasers for the treatment of vulvovaginal atrophy. *Curr Opin Obstet Gynecol* 27(6):504–508
  13. Gaspar A, Brandi H, Gomez V, Luque D (2017) Efficacy of erbium: YAG laser treatment compared to topical estriol treatment for symptoms of genitourinary syndrome of menopause. *Lasers Surg Med* 49(2):160–168
  14. Salvatore S, Leone Roberti Maggiore U, Athanasiou S, Origoni M, Candiani M, Calligaro A, Zerbini N (2015) Histological study on the effects of microablative fractional CO2 laser on atrophic vaginal tissue: an ex vivo study. *Menopause* 22(8):845–849. <https://doi.org/10.1097/GME.0000000000000401>
  15. Sokol ER, Karram MM (2016) An assessment of the safety and efficacy of a fractional CO2 laser system for the treatment of vulvovaginal atrophy. *Menopause* 23(10):1102–1107. <https://doi.org/10.1097/GME.0000000000000700>
  16. Athanasiou S, Pitsouni E, Antonopoulou S, Zacharakis D, Salvatore S, Falagas ME, Grigoriadis T (2016) The effect of microablative fractional CO2 laser on vaginal flora of postmenopausal women. *Climacteric : the journal of the International Menopause Society* 19(5):512–518. <https://doi.org/10.1080/13697137.2016.1212006>
  17. Pitsouni E, Grigoriadis T, Tsiveleka A, Zacharakis D, Salvatore S, Athanasiou S (2016) Microablative fractional CO2-laser therapy and the genitourinary syndrome of menopause: an observational study. *Maturitas* 94:131–136. <https://doi.org/10.1016/j.maturitas.2016.09.012>
  18. Murina F, Karram M, Salvatore S, Felice R (2016) Fractional CO2 laser treatment of the vestibule for patients with vestibulodynia and genitourinary syndrome of menopause: a pilot study. *J Sex Med* 13(12):1915–1917. <https://doi.org/10.1016/j.jsxm.2016.10.006>
  19. Pieralli A, Fallani MG, Becorpi A, Bianchi C, Corioni S, Longinotti M, Tredici Z, Guaschino S (2016) Fractional CO2 laser for vulvovaginal atrophy (VVA) dyspareunia relief in breast cancer survivors. *Arch Gynecol Obstet* 294(4):841–846. <https://doi.org/10.1007/s00404-016-4118-6>
  20. Muhleisen AL, Herbst-Kralovetz MM (2016) Menopause and the vaginal microbiome. *Maturitas* 91:42–50. <https://doi.org/10.1016/j.maturitas.2016.05.015>
  21. Campisciano G, Florian F, D'Eustacchio A, Stankovic D, Ricci G, De Seta F, Comar M (2017) Subclinical alteration of the cervical-vaginal microbiome in women with idiopathic infertility. *J Cell Physiol* 232(7):1681–1688. <https://doi.org/10.1002/jcp.25806>
  22. Zanolta N, Tomesello ML, Annunziata C, Stellato G, Buonaguro FM, Comar M (2016) Candidate soluble immune mediators in young women with high-risk human papillomavirus infection: high expression of chemokines promoting angiogenesis and cell proliferation. *PLoS One* 11(3):e0151851. <https://doi.org/10.1371/journal.pone.0151851>
  23. Donders GG, Bosmans E, Dekeersmaecker A (2000) Pathogenesis of abnormal vaginal bacterial flora. *Am J Obstet Gynecol* 182:872–878
  24. Galen BT, Martin AP, Hazrati E (2007) A comprehensive murine model to evaluate topical vaginal microbicides: mucosal inflammation and susceptibility to genital herpes as surrogate markers of safety. *J Infect Dis* 195:1332–1339
  25. Petricevic L, Unger FM, Viemstein H (2008) Randomized, double-blind, placebo-controlled study of oral lactobacilli to improve the vaginal flora of postmenopausal women. *Eur J Obstet Gynecol Reprod Biol* 141:54–57
  26. Fichorova RN, Lai JJ, Schwartz JL (2011) Baseline variation and associations between subject characteristics and five cytokine biomarkers of vaginal safety among healthy non-pregnant women in microbicide trials. *Cytokine* 55:134–140
  27. Salvatore S, Nappi RE, Zerbini N (2014) A 12-week treatment with fractional CO2 laser for vulvovaginal atrophy: a pilot study. *Climacteric* 17:363–369. <https://doi.org/10.3109/13697137.2014.899347>
  28. Tierney EP, Hanke CW (2009) Ablative fractionated CO2, laser resurfacing for the neck: prospective study and review of the literature. *J Drugs Dermatol* 8(8):723–731
  29. Abrahamse H (2012) Regenerative medicine, stem cells, and low-level laser therapy: future directives. *Photomed Laser Surg* 30(12):681–682. <https://doi.org/10.1089/pho.2012.9881>
  30. Prignano F, Campolmi P, Bonan P, Ricceri F, Cannarozzo G, Troiano M, Lotti T (2009) Fractional CO2 laser: a novel therapeutic device upon photobiomodulation of tissue remodeling and cytokine pathway of tissue repair. *Dermatol Ther* 22(Suppl 1):S8–15. <https://doi.org/10.1111/j.1529-8019.2009.01265.x>
  31. Sica A, Invernizzi P, Mantovani A (2014) Macrophage plasticity and polarization in liver homeostasis and pathology. *Hepatology* 59(5):2034–2042. <https://doi.org/10.1002/hep.26754>
  32. Brotman RM, Shardell MD, Gajer P, Fadrosh D, Chang K, Silver MI, Viscidi RP, Burke AE, Ravel J, Gravitt PE (2014) Association between the vaginal microbiota, menopause status, and signs of vulvovaginal atrophy. *Menopause* 21(5):450–458. <https://doi.org/10.1097/GME.0b013e3182a4690b>
  33. Shen J, Song N, Williams CJ, Brown CJ, Yan Z, Xu C, Forney LJ (2016) Effects of low dose estrogen therapy on the vaginal microbiomes of women with atrophic vaginitis. *Sci Rep* 6:24380. <https://doi.org/10.1038/srep24380>